

## Structural and Functional Changes in the Brains of Guitarist Musicians: Volumetric, VBM, and Resting State fMRI Study

 Niyazi Acer,<sup>1</sup>  Burcu Kamaşak Arpaçay,<sup>2</sup>  Serap Bastepe Gray,<sup>3</sup>  Burak Oğuzhan Karapınar,<sup>4</sup>  Funda İpekten,<sup>5</sup>  Levent Değirmencioğlu,<sup>6</sup>  Ahmet Turan İlica<sup>7</sup>

<sup>1</sup>Department of Anatomy, Arel University Faculty of Medicine, İstanbul, Türkiye

<sup>2</sup>Department of Anatomy, Kirsehir Ahi Evran University Faculty of Medicine, Kirsehir, Türkiye

<sup>3</sup>Department of Neurology, The Peabody Conservatory, Johns Hopkins University, Baltimore, USA

<sup>4</sup>Department of Medical Services and Techniques, Ondokuz Mayıs University, Vocational School of Health Services, Samsun, Türkiye

<sup>5</sup>Department of Biostatistics, Erciyes University Faculty of Medicine, Kayseri, Türkiye

<sup>6</sup>Department of Music, Erciyes University Faculty of Fine Arts, Kayseri, Türkiye

<sup>7</sup>Department of Radiology, Memorial Sloan Kettering Cancer Center, New York City, USA



### Cite this article as:

Acer N, Kamaşak Arpaçay B, Bastepe Gray S, Karapınar BO, İpekten F, Değirmencioğlu L, İlica AT. Structural and Functional Changes in the Brains of Guitarist Musicians: Volumetric, VBM, and Resting State fMRI Study. J Clin Pract Res 2024; 46(1): 47–57.

### Address for correspondence:

Burcu Kamaşak Arpaçay,  
Department of Anatomy,  
Kirsehir Ahi Evran University  
Faculty of Medicine, Kirsehir,  
Türkiye  
**Phone:** +90 545 282 89 02  
**E-mail:** brc1608@hotmail.com

**Submitted:** 18.07.2023

**Revised:** 07.12.2023

**Accepted:** 07.02.2024

**Available Online:** 19.02.2024

Erciyes University Faculty of  
Medicine Publications -  
Available online at [www.jcprres.com](http://www.jcprres.com)



This work is licensed under  
a Creative Commons  
Attribution-NonCommercial  
4.0 International License.

### ABSTRACT

**Objective:** Musicians acquire intricate motor and auditory skills from an early age, serving as an exemplary model for brain plasticity. This study aimed to investigate the structural and functional differences in the brains between guitar-playing musicians and non-musicians.

**Materials and Methods:** Cortical thickness measurements, volumetric analysis of the corpus callosum and hippocampus, voxel-based morphometry (VBM), and resting-state functional magnetic resonance imaging (fMRI) were applied to a magnetic resonance imaging dataset from 14 male young adult guitar players and 10 matched non-musicians.

**Results:** A structural asymmetry, mainly localized to hippocampal regions including the stratum radiatum, lacunosum, and moleculare, was found in the musicians' group. VBM analysis demonstrated increased volume in the frontal middle and inferior gyri (left), precuneus (right), insula (right), and Brodmann areas 7 and 13 in the musician group compared to non-musicians. There were no statistical differences between musicians and non-musicians in terms of corpus callosum and hippocampal subfield volumes. Although cortical thickness measured at different locations was higher in the musician group than in the non-musician group, these differences were not statistically significant ( $p > 0.05$ ). No significant functional connectivity alterations were found within the default mode network between musicians and non-musicians ( $p > 0.05$ ).

**Conclusion:** Playing a musical instrument triggers rapid integration of multi-sensory information in the context of musical performance. The functional state of rest has contributed significantly to understanding musicians' brain networks.

**Keywords:** Cortical thickness, resting state fMRI, musician, voxel-based morphometry, brain.

## INTRODUCTION

Playing a musical instrument requires complex motor activity. Musicians interpret the notes they visually perceive and perform the corresponding rhythmic finger movements.<sup>1</sup> Instrument players exhibit strong sensorimotor and multisensory integration between the music's rhythm and hand movements. They are also adept at complex physical and mental operations, such as memorizing lengthy musical passages and identifying tones without assistance from any reference tone.<sup>2,3</sup>

Musicians often begin their musical education in childhood and dedicate part of their day to this training. For this reason, professional musicians provide an excellent model for examining volumetric differences and brain plasticity among brain structures that may result from music education.<sup>1</sup>

Numerous neuroimaging studies have demonstrated that sustained musical instruction leads to functional and structural changes in the brain. Recent research has focused on the functional and structural differences between the brains of musicians and non-musicians. Compared to non-musicians, musicians' brains show a greater volume of gray matter (GM) in motor and visuospatial regions. Professional musicians, in particular, exhibit a significant increase in the volume of their auditory cortex, especially in Heschl's gyrus.<sup>2,4,5</sup>

Changes in the brain structure of musicians are not confined to auditory areas or GM alone. In professional pianists, a similar increase in volume and a more complex gyration pattern are observed in the hand-representing region of the motor homunculus. There is also enhanced efficiency in information transmission between regions of the auditory cortex in the white matter network of professional musicians.<sup>6–8</sup> In addition, significant differences were found in the structural features of the brains of musicians and non-musicians, particularly in the corpus callosum, cerebellum, and some regions including Broca's area.<sup>2,4,9–11</sup>

The hippocampus has been shown to play a crucial role in cognition, especially in memory operations, including episodic, semantic, and spatial memory.<sup>12</sup> Furthermore, it is known that musicians' auditory and visual working memory is updated faster than that of non-musicians.<sup>13</sup>

We propose that the hippocampus and corpus callosum are the main anatomical areas showing structural differences in the brains of musicians. In the present study, we aimed to demonstrate structural and functional changes using resting-state functional magnetic resonance imaging (fMRI) to enhance our understanding of how the brain of a musician processes creative behaviors.

## MATERIALS AND METHODS

This cohort study utilized resting-state fMRI study, along with volumetry and voxel-based morphometry. The study was approved by the Erciyes University Ethical Committee (2014-KAEK-122) and was supported by the Erciyes University Scientific Research Projects Coordination Unit under grant number TIR-2017-5045. Analyses were conducted on data collected and images obtained between 2017 and 2019 with the start of the project.

Volunteers signed an informed consent form. The subjects consisted of 14 musicians with professional training, whose primary instrument was the guitar, having a mean age of 22.8 years (aged 21–26); all subjects were male. The training period for playing the guitar varied between 10 and 18 years among subjects. The average age of starting to play the guitar was 10, and the minimum weekly instrument playing time was 10 hours.

The control group included 10 non-musicians (all male), defined as individuals without any prior musical instrument playing expertise. Each subject gave informed consent before participating. All participants were right-handed.

### Magnetic Resonance Imaging (MRI) Protocol

MRI examinations were conducted using a 1.5 Tesla Siemens Aera scanner (Siemens, Germany) equipped with an 8-channel sense head coil. Patients were positioned supinely. Survey images and T1-weighted 3D-MPRAGE sequences with contiguous coronal slices were obtained (TE: 2.84 ms, TR: 1900 ms, slice thickness: 1 mm, flip angle: 5°, field of view: 280 mm, matrix: 256 x 256, voxel size: 1 x 1 x 1 mm<sup>3</sup>).

The resting-state fMRI session consisted of acquiring 300 brain images using echo-planar imaging (EPI) with the following parameters: 36 slices per volume, repetition time (TR)=3000 ms, echo time (TE)=25 ms, flip angle=90°, resolution: 2 x 2 x 2 mm<sup>3</sup>, and slice thickness=1 mm. During resting-state data acquisition, participants were instructed to keep their eyes closed.

### Volumetric MRI Measurements (VolBrain, MRICloud, Voxel-Based Morphometry (VBM), and Cortical Thickness) VolBrain and MRICloud

The T1-weighted images were uploaded to the MRI brain volumetry system, volBrain, for brain volumetric analysis. The volume of hippocampal segments and the ratio of total hippocampal volume to intracranial volume were calculated using volBrain. VolBrain [v.1.0, <http://volbrain.upv.es>] is a complimentary web-based system designed for calculating MRI brain volumes. It utilizes a fully automated

**Table 1.** Volumetric values of corpus callosum subfield segmentation

Corpus callosum volumes	Musicians	Non-musicians	p
Genu (cm <sup>3</sup> )	4.92±1.14	5.21±1.65	0.731
Body (truncus) (cm <sup>3</sup> )	7.31±1.25	7.18±1.99	0.525
Splenium (cm <sup>3</sup> )	12.65±1.34	12.65±3.88	0.524
Total corpus callosum (cm <sup>3</sup> )	24.84±3.27	25.03±7.11	0.824
CC/TIV (%)	2.19±0.2	2.04±0.47	0.791

Values are expressed as mean±SD. CC: Corpus callosum; TIV: Total intracranial volume.

**Table 2.** Volumetric values of corpus callosum subfield segmentation

Regions	Groups		p
	Control (n=10)	Musicians (n=14)	
GCC	9.5 (-8.9/15.2)	8.0 (0.3/12.9)	0.781
BCC	-4.8 (-7.6/3.0)	-3.8 (-6.1/3.7)	0.764
SCC	3.8 (1.5/6.1)	3.7 (-1.6/6.4)	0.647
Hippocampus	0.4 (-2.3/3.0)	5.3 (2.9/6.1)	<b>0.021</b>
CA1	-1.2 (-5.1/7.8)	3.8 (0.9/12.4)	0.166
CA2-3	12.7 (5.4/25.7)	21.2 (7.8/35.9)	0.343
CA4-DG	5.2 (-4.3/13.1)	2.0 (-3.5/9.8)	0.781
SR/SL/SM	-2.4 (-8.4/3.1)	5.6 (-0.6/10.0)	<b>0.028</b>
Subiculum	-12.5 (-16.1/-4.0)	-3.0 (-16.5/3.3)	0.546

Values are expressed as the median (1<sup>st</sup>-3<sup>rd</sup> quartiles). BCC: Body of corpus callosum; CA: Cornu ammonis; DG: Dentate gyrus; GCC: Genu of corpus callosum; SCC: Splenium of corpus callosum; SR/SL/SM: Stratum radiatum/stratum lacunosum/stratum moleculare.

segmentation technique based on multi-atlas patch-based label fusion segmentation technology.<sup>14</sup> The average processing time is 5 minutes.

MRICloud provides a neuroinformatics platform offering high throughput, enabling automated segmentation of brain MRI and analytical tools for quantification. This is achieved through distributed remote computation and user interfaces accessible via the web. The T1-weighted images were segmented using MRICloud, available at [www.mricloud.org](http://www.mricloud.org). The accuracy of segmentation with multi-atlas fusion has been validated in contrast to single atlas approaches. The brain was segmented into 289 structures, including the corpus callosum and its segments, among others. The volumes of intracranial structures were obtained based on T1 segmentation.<sup>15</sup>

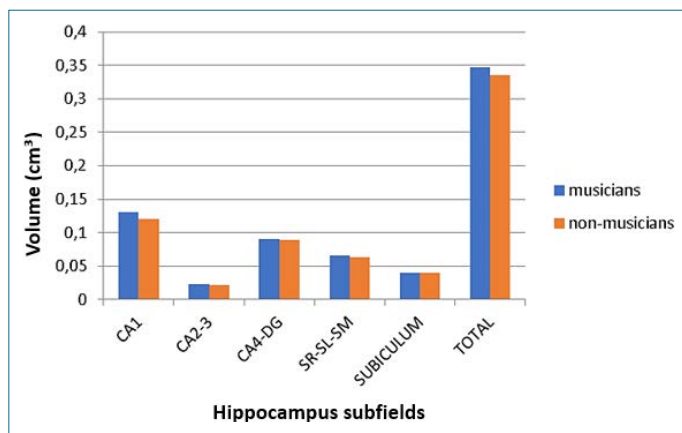
We utilized web-based and automated tools, volBrain and MRICloud, to measure the volumes of the corpus callosum and hippocampus. Outputs include the volumes of the hippocampus and corpus callosum (CC) in cm<sup>3</sup>, the ratio of

hippocampal volume to total intracranial volume, expressed using volBrain and MRICloud.

The Asymmetry Index (AI) is determined by dividing the mean hippocampus volumes of the right and left sides by their respective means, expressed as a percentage.  $AI = (left - right) \times 100 / (left + right)$ .<sup>14</sup>

#### Voxel Based Morphometry (VBM) Analysis

Volumetric brain analysis was performed using CAT12 (Computational Anatomy Toolbox) within Statistical Parametric Mapping (SPM12) in Matlab 7.10.0 (R2010a). Sagittal T1 DICOM (Digital Imaging and Communications in Medicine) images were converted to NIFTI-1 (Neuroimaging Informatics Technology Initiative) format. Total intracranial volume (TIV) and overall tissue volume (TTV) were determined using white matter (WM), gray matter (GM), and cerebrospinal fluid (CSF). The Automated Anatomical Labeling Atlas was used alongside one of the SPM toolboxes to calculate lobar GM volumes.



**Figure 1.** Volumetric values ( $\text{cm}^3$ ) of Hippocampus subfield segmentation.

CA: Cornu ammonis; DG: Dentate gyrus; SR/SL/SM: Stratum radiatum/stratum lacunosum/stratum moleculare.

VBM is based on voxel-wise statistics. The General Linear Model is used to determine regions with significant differences. An independent t-test was carried out to compare GM volume between two groups, taking into account variables such as age, years of schooling, and TIV. These analyses employed a  $p < 0.001$  uncorrected threshold, which is less conservative.

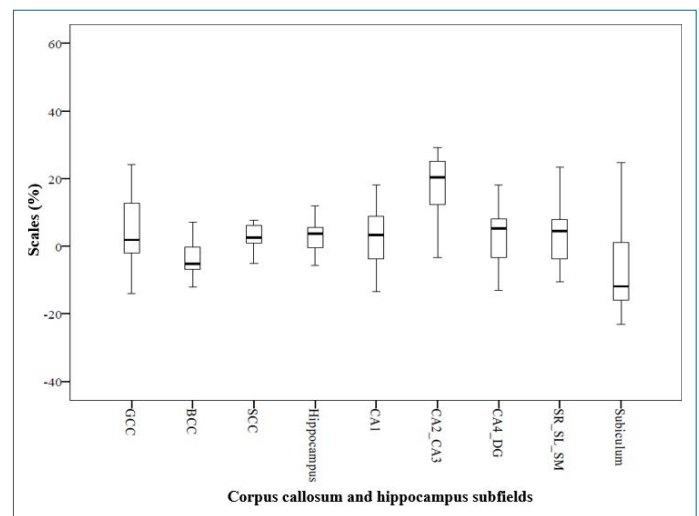
For the region of interest (ROI) study, volumes were segmented using surface and thickness estimation techniques. Following segmentation, the local maximum was projected onto other GM voxels via a connection determined by the WM distance. The data were then visually examined.

### The Connectivity (CONN) Toolbox

Resting-state fMRI (rs-fMRI) preprocessing was conducted using the SPM12 software along with the CONN Toolbox (<http://www.nitrc.org/projects/conn>).<sup>16</sup>

By utilizing CONN, we achieved functional outlier detection, functional slice time correction, functional realignment and unwarping, and functional centering. In the first level analysis, CONN's atlases, networks, Brodmann areas (BAs) files, as well as WM, GM, and CSF segments identified by SPM, were used as ROIs. The ROI to ROI analysis, a key component of CONN, was conducted. Group-level estimates of the linkage between ROIs were performed using the default mode network (DMN) nodes as the core, and differences between groups were identified.

T- and F-statistics in the CONN toolbox facilitated the statistical analysis. An independent t-test was used for group comparisons. Uncorrected and cluster-level thresholds of



**Figure 2.** Median values of the hippocampus and corpus callosum subfield segments.

GCC: Genu of corpus callosum; BCC: Body of corpus callosum; SCC: Splenium of corpus callosum; CA: Cornu ammonis; DG: Dentate gyrus; SR/SL/SM: Stratum Radiatum/stratum lacunosum/stratum moleculare.

$p < 0.05$  and  $p < 0.001$  for significant correlations, respectively, were set. ROI to ROI connectivity maps, indicating connectivity strength and polarity, were plotted, with thresholding applied using a False Discovery Rate-adjusted p-value (p-FDR) of 0.05.

### Statistical Analysis

Q-Q graphs and histograms were analyzed. The Kolmogorov-Smirnov and Shapiro-Wilk tests were used to assess data normality. Variance homogeneity was examined using the Levene test. Group comparisons were made using an independent t-test and the Mann-Whitney U test. The study's data were analyzed using the Statistical Package for the Social Sciences (SPSS) 22.0 for Windows (IBM, Armonk, NY, USA).

## RESULTS

### Volume Results

The volumes of corpus callosum segments in musicians and non-musicians are summarized in Table 1. There was no statistically significant difference between the two groups ( $p > 0.05$ ).

The hippocampal volume was measured as  $5.23 \pm 0.44 \text{ cm}^3$  in musicians and  $5.31 \pm 0.52 \text{ cm}^3$  in non-musicians. In musicians, the ratio of total hippocampal volume to intracranial volume was  $0.34\% \pm 0.03$ , and in the control group, it was  $0.33\% \pm 0.02$ . No statistically significant difference was observed between the two groups ( $p > 0.05$ ) (Fig. 1).

The median values of the hippocampus and corpus callosum subfield segments for all participants are shown in Figure 2.

**Table 3.** Clusters of significant gray matter reduction in musicians compared to non-musicians using uncorrected maps at  $p < 0.001$  (extent threshold voxels: 25)

Regions	Number of voxels (mm <sup>3</sup> )	MNI coordinates (x, y, z)	Peak Z score	T value	P value (set level p uncorrected)
Cluster 1 Frontal_Mid_L (aal) (37) Frontal_Inf_L (aal) (8)	45	-41, 50, 11	4.16	5.60	0.995
Cluster 2 Precuneus_R (aal) (74) BA 7 (47)	74	8, -63, 57	4.01	5.28	
Cluster 3 BA 13 (16) Insula_R (14)	25	38, 21, 11	3.40	4.14	

The p-value has been calculated with voxel-wise statistics. aal: Automated anatomical labeling; BA: Brodmann area; Inf: Inferior; L: Left; Mid: Middle; MNI: Montreal Neurological Institute; R: Right; Tri: Triangular.

**Table 4.** Clusters of significant gray matter reduction in non-musicians compared to musicians using uncorrected maps at  $p < 0.001$  (extent threshold voxels: 45)

Regions	Number of voxels (mm <sup>3</sup> )	MNI coordinates (x, y, z)	Peak Z score	T value	P value (set level p uncorrected)
Cluster 1 Temporal Lobe (52) Fusiform_R (aal) (8)	57	29, -51, -2	3.69	4.66	0.896
Cluster 2 Cerebellum_4_5_L (aal) (45)	45	-8, -48, -18	3.29	3.97	
Cluster 3 Occipital_Inf_L (aal) (47)	55	-38, -68, -8	4.21	5.70	

The p-value has been calculated with voxel-wise statistics. aal: Automated anatomical labeling; Inf: Inferior; L: Left; MNI: Montreal Neurological Institute; R: Right.

### Asymmetry Index Results

Compared with the non-musicians group, the musicians group exhibited a greater Asymmetry Index (AI) for total hippocampal volume ( $p=0.021$ ) and higher AI in the Stratum Radiatum/Stratum Lucidum/Stratum Moleculare (SR/SL/SM) ( $p=0.028$ ) and Cornu Ammonis 1 (CA1), Cornu Ammonis 2 and 3 (CA2-3) segments. However, there was no statistically significant difference between the two groups (Table 2). No significant differences in asymmetry of the corpus callosum and its subfields were observed between musicians and non-musicians.

### VBM Results

The musicians exhibited an increase in the volume of the precuneus (right), middle frontal gyrus (left), insula (right),

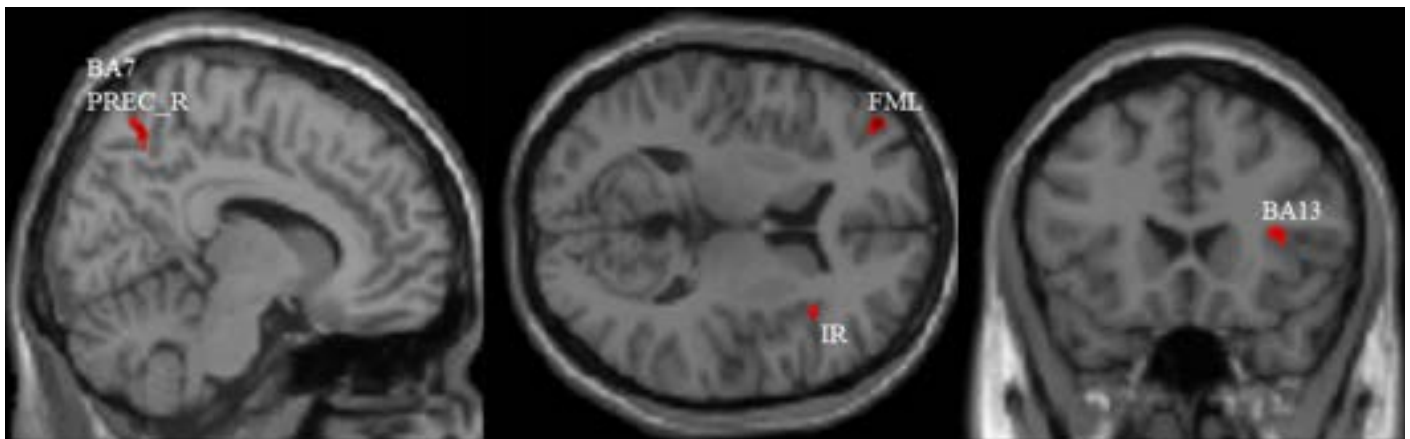
and Brodmann areas 7 and 13 compared to non-musicians. An increase in GM volume in the fusiform gyrus (right) in the musician group was found compared to non-musicians (Fig. 3, 4, Table 3, 4).

### Cortical Thickness Results

Although a slight increase in cortical thickness was observed in the motor, auditory, and visuospatial brain regions of musicians, this increase was not significant ( $p > 0.05$ ) (Table 5).

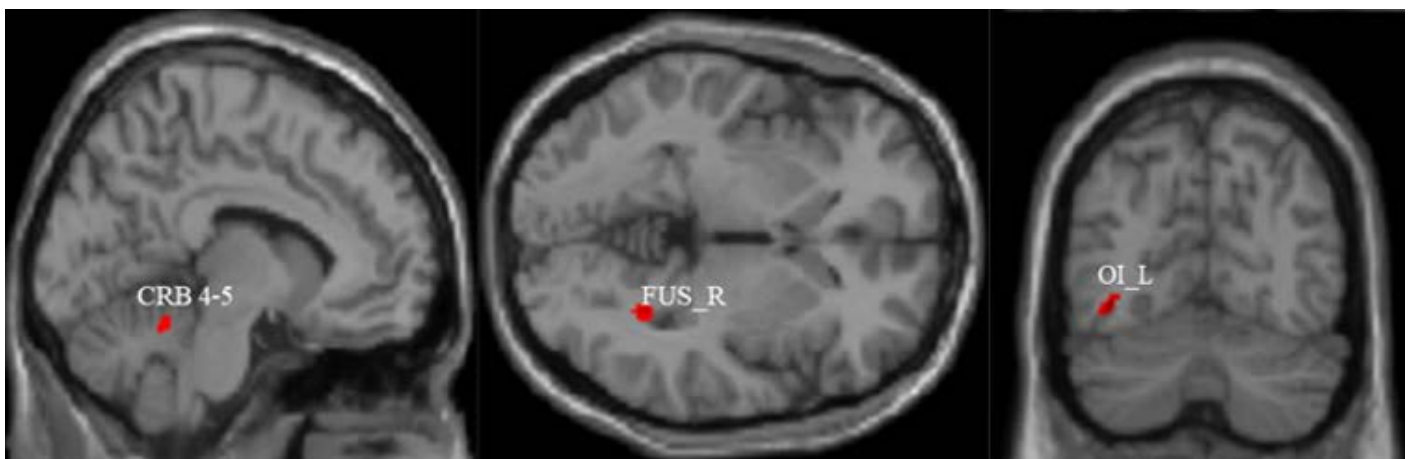
### CONN Results

At the voxel level, there were no significant differences between the two groups. No significant alterations in the frontal cortex or the default mode network (DMN) between musicians and non-musicians were found ( $p > 0.05$ ).



**Figure 3.** Altered gray matter volume in musicians and non-musicians in single T1 images ( $p < 0.001$ , uncorrected). The red area indicates an increase in volume within the musician group.

FML: Frontal middle left; IR: Insula right; PREC\_R: Precuneus right; BA13: Brodmann area 13.



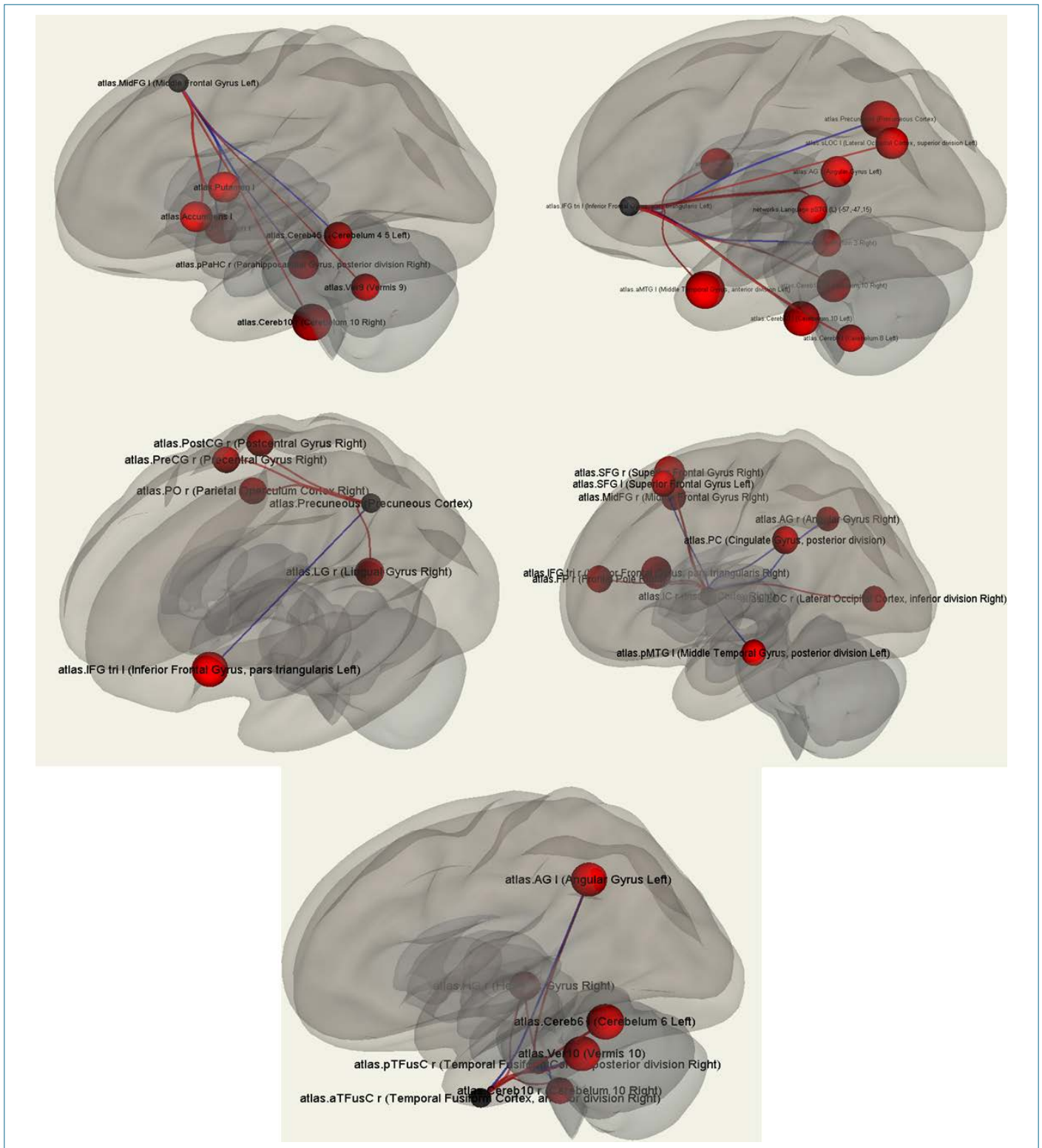
**Figure 4.** Altered gray matter volume in musicians and non-musicians in single T1 images ( $p < 0.001$ , uncorrected). The red area indicates a decrease in volume within the musician group.

CRB: Cerebellum; FUS\_R: Fusiform right; OI\_L: Occipital inferior left.

ROIs across brain networks were examined, including each ROI of resting-state networks (RSNs) as follows: DMN, middle prefrontal cortex (MPFC), anterior insular cortex, inferior frontal cortex, precuneus, and fusiform cortex. Figure 5 shows the connections between the source region and other brain regions in musicians minus non-musicians. Increased brain network connectivity was observed in musicians compared to non-musicians. In terms of ROI to ROI connectivity, our study yielded some striking results. However, the DMN ROIs between the two groups did not show any significant positive or negative correlations.

## DISCUSSION

The objective of our research was to identify the anatomical and functional alterations in the brain potentially caused by playing the guitar. We assessed the volumes of the corpus callosum and hippocampus using web-based morphometry tools (volBrain and MRICloud), evaluated the differences in gray matter (GM) volume using VBM, and examined functional connectivity using the CONN toolbox. To our knowledge, this is the first study to compare the volumes of hippocampal and corpus callosum subfields, resting-state functional differences, and cortical thicknesses between musicians and non-musicians.



**Figure 5.** ROI-to-ROI functional connectivity between networks: the middle prefrontal cortex **(a)** (MPFC), inferior frontal cortex **(b)**, anterior insular cortex **(c)**, precuneus **(d)**, and fusiform cortex **(e)** serves as sources. The black sphere indicates the source point. The red spheres represent functional connections between the source and other ROI regions in the brain.

**Table 5.** Cortical thickness values for musicians and non-musicians

Brain region	Group		p	Brain region	Group		p
	Musicians (n=10)	Non-musicians (n=10)			Musicians (n=10)	Non-musicians (n=10)	
L anterior orbital gyrus	0.68±0.13	0.66±0.09	0.633	R medial postcentral gyrus	0.98±0.29	0.96±0.37	0.908
R anterior orbital gyrus	0.68±0.11	0.64±0.13	0.433	L medial precentral gyrus	1.37±0.39	1.43±0.45	0.725
L central operculum	1.00±0.14	0.98±0.15	0.692	R medial precentral gyrus	1.15±0.29	1.16±0.30	0.917
R central operculum	0.96±0.15	0.97±0.13	0.532	L middle temporal gyrus	3.71±0.59	3.65±0.56	0.797
L frontal operculum	0.52±0.06	0.50±0.08	0.374	R middle temporal gyrus	3.14±0.59	2.99±0.45	0.493
R frontal operculum	0.42±0.06	0.42±0.08	0.869	L occipital fusiform gyrus	0.76±0.15	0.72±0.15	0.472
L frontal pole	3.52±0.85	3.46±0.88	0.870	R occipital fusiform gyrus	0.92±0.17	0.85±0.14	0.309
R frontal pole	3.81±0.92	3.83±0.88	0.921	L inferior frontal gyrus	1.84±0.35	1.87±0.41	0.825
L fusiform gyrus	1.59±0.32	1.59±0.38	0.991	R inferior frontal gyrus	1.83±0.40	1.93±0.35	0.540
R fusiform gyrus	1.53±0.30	1.48±0.21	0.659	L postcentral gyrus	8.19±1.73	8.20±2.41	0.879
L inferior occipital gyrus	2.27±0.31	2.11±0.42	0.284	R postcentral gyrus	7.45±1.67	7.20±2.07	0.755
R inferior occipital gyrus	2.29±0.37	2.02±0.31	0.081	L precentral gyrus	7.44±1.35	7.29±1.77	0.815
L inferior temporal gyrus	3.24±0.52	3.05±0.61	0.427	R precentral gyrus	6.61±1.13	6.72±1.60	0.717
R inferior temporal gyrus	3.29±0.59	3.21±0.63	0.755	L temporal	0.47±0.07	0.48±0.13	0.860
L lingual gyrus	2.74±0.63	2.67±0.38	0.736	R temporal	0.33±0.08	0.31±0.07	0.569
R lingual gyrus	2.76±0.69	2.66±0.46	0.689	L superior frontal gyrus	10.87±1.94	10.87±2.32	0.999
L lateral orbital gyrus	1.12±0.27	1.08±0.27	0.699	R superior frontal gyrus	11.06±2.29	11.19±2.50	0.896
R lateral orbital gyrus	1.05±0.29	1.05±0.21	0.954	L superior parietal lobule	7.31±1.80	7.12±2.07	0.817
L medial frontal cerebrum	0.31±0.08	0.31±0.05	0.900	R superior parietal lobule	7.69±1.94	7.30±1.70	0.614
R medial frontal cerebrum	0.32±0.10	0.33±0.06	0.842	L superior temporal gyrus	2.17±0.43	2.18±0.36	0.851
L middle frontal gyrus	9.75±2.09	9.65±2.40	0.923	R superior temporal gyrus	2.41±0.37	2.42±0.50	0.964
R middle frontal gyrus	9.57±1.97	9.41±2.16	0.856	L temporal pole	5.14±0.94	5.49±1.05	0.413
L middle occipital gyrus	2.24±0.46	2.01±0.42	0.239	R temporal pole	5.35±1.07	5.53±1.17	0.703
R middle occipital gyrus	1.45±0.23	1.27±0.32	0.123	L temporal transverse gyrus	0.27±0.06	0.27±0.05	0.833
L medial postcentral gyrus	0.99±0.27	0.98±0.31	0.964	R temporal transverse gyrus	0.26±0.06	0.25±0.05	0.600

Data are expressed as mean±standard deviation. L: Left; R: Right.

In this study, musicians exhibited an increase in volume in the frontal middle and inferior gyri (left), precuneus (right), insula (right), and Brodmann areas 7 and 13 compared to non-musicians, as determined by VBM analysis. We also observed an increased volume of GM in the fusiform gyrus (right) in musicians compared to non-musicians.

Several authors have reported that playing different instruments causes structural changes in the brains of musicians.<sup>6,17</sup> It is known that musicians exhibit increased activation in multiple core brain regions, including the sensory cortex, auditory cortex, motor cortex, cerebellum,

prefrontal cortex, visual cortex, hippocampus, corpus callosum, nucleus accumbens, and amygdala.<sup>18</sup> Structural differences between musicians and non-musicians have been identified in areas such as Broca's area and the inferior frontal gyrus (4, 11), Heschl's gyrus or primary auditory cortex (5), as well as in the areas of the superior parietal lobule (4) and cerebellum (9). Several studies utilizing VBM have provided insights into the characteristics of the subjects, techniques, and results.<sup>1,4,11,19–24</sup>

Acer et al.<sup>1</sup> (2018) applied VBM to seven musicians and non-musicians, finding increased GM volume in musicians in

the left middle temporal gyrus, supramarginal and angular gyri, right and left cerebellum, left superior and inferior parietal lobule.

Marie et al.<sup>23</sup> (2023) observed that GM volume increased in the right Rolandic operculum, left caudate nucleus, and lobules VIII of the left and right cerebellum in both group after six months of a piano and music sensitization course in elderly individuals. Another study highlighted the highly positive brain plasticity in frontal regions of musicians. When comparing older musicians to older non-musicians, it was found that musicians exhibit slower brain atrophy and greater cortical thickness and GM volume in areas associated with music.<sup>3</sup>

In our research, a significant increase was observed in the right fusiform gyrus and the left inferior and middle frontal gyri using VBM. The literature indicates that the left inferior frontal gyrus is crucial for syntax processing in both language and music.<sup>24</sup> The right fusiform gyrus is known for its role in symbolic processing through visual form identification.<sup>25</sup>

According to Bermudez et al.<sup>19</sup> (2009), musicians had a thicker cortex with peaks in the dorsolateral frontal and superior temporal regions. Furthermore, musicians have thicker lateral frontal lobes with prominent bilateral peaks in the inferior and middle frontal gyri. In our study, musicians exhibited slightly thicker cortical tissue in the inferior and middle frontal gyri, although the difference between the two groups was not statistically significant.

Resting-state fMRI studies have shown strong correlations between some regions in the supplementary motor areas (SMAs), the precentral gyrus, and a close correlation between precentral areas and SMAs in the musician group.<sup>26–29</sup>

Each cluster served as a seed location for generating and comparing whole-brain resting-state functional connectivity maps by Fauvel et al.<sup>21</sup> The left temporal pole and right prefrontal cortex, which are involved in the semantic system, showed increased connectivity to two clusters in the cingulate gyrus in musicians. Several language-related regions, including the bilateral supramarginal gyri and the left premotor cortex, demonstrated increased connectivity with the cluster in the left superior temporal gyrus. Fauvel et al.<sup>21</sup> observed that musicians exhibited greater resting-state functional connectivity with primary sensorimotor cortex, high-level cognitive areas, and subcortical structures compared to non-musicians. They utilized the left superior temporal gyrus, right cingulate gyrus, and right inferior orbito-frontal gyrus as seeds. Butler et al.<sup>30</sup> (2021) discovered that for guitarists, the right precuneus is more active during abstract teaching, while the occipito-insular circuit is more engaged during concrete teaching. In our study, we employed each

cluster as a seed region to compare whole-brain resting-state functional connectivity maps. The middle prefrontal cortex, inferior frontal cortex, anterior insular cortex, precuneus, and fusiform cortex exhibited greater connectivity in musicians.

### Limitations

This study has some limitations. Primarily, the sample size was comparatively small for a cortical thickness and VBM study. Additionally, all participants in this sample were male. Future studies will aim to expand the current approach to a larger sample size and include both sexes.

### CONCLUSION

The brains of musicians were found to be structurally different from those of non-musicians according to VBM results in this study. Our findings suggest that playing musical instruments might alter the structural properties of nearby anatomical regions and foster the creation of new, functional neural networks in the brain. While no structural brain differences were observed at the volumetric level in the hippocampus and CC, we did identify differences in asymmetry indices.

This study highlighted altered morphological interhemispheric imbalances in musicians, mainly located in the hippocampal regions, especially the SR/SM/SL regions. Structural brain differences in hippocampal asymmetry may be related to memory processes. These alterations, independent of the anatomical brain differences in musicians, suggest that cerebral asymmetry could serve as an appropriate indicator of morphological variations in musicians' brains. In conclusion, the resting-state functional situation has significantly contributed to our understanding of the musical brain network.

**Ethics Committee Approval:** The Erciyes University Clinical Research Ethics Committee granted approval for this study (date: 21.02.2014, number: 2014-KAEK-122).

**Author Contributions:** Concept – SBG; Design – NA, SBG; Supervision – BKA; Resource – NA; Materials – LD; Data Collection and/or Processing – NA, LD; Analysis and/or Interpretation – NA, BKA, Fİ; Literature Search – BOK; Writing – NA, BKA, BOK; Critical Reviews – ATI.

**Conflict of Interest:** The authors have no conflict of interest to declare.

**Informed Consent:** Written informed consent was obtained from patients who participated in this study.

**Use of AI for Writing Assistance:** Not declared.

**Financial Disclosure:** We acknowledge the support of the Erciyes University Scientific Research Projects Coordination Unit under grant number TIR-2017-5045.

**Peer-review:** Externally peer-reviewed.

## REFERENCES

1. Acer N, Bastepe-Gray S, Sagiroglu A, Gumus KZ, Degirmencioglu L, Zararsiz G, et al. Diffusion tensor and volumetric magnetic resonance imaging findings in the brains of professional musicians. *J Chem Neuroanat* 2018; 88: 33–40.
2. Gaser C, Schlaug G. Gray matter differences between musicians and nonmusicians. *Ann N Y Acad Sci* 2003; 999: 514–7.
3. Rus-Oswald OG, Benner J, Reinhardt J, Bürki C, Christiner M, Hofmann E, et al. Musicianship-related structural and functional cortical features are preserved in elderly musicians. *Front Aging Neurosci* 2022; 14: 807971.
4. Gaser C, Schlaug G. Brain structures differ between musicians and non-musicians. *J Neurosci* 2003; 23: 9240–5.
5. Schneider P, Sluming V, Roberts N, Bleeck S, Rupp A. Structural, functional, and perceptual differences in Heschl's gyrus and musical instrument preference. *Ann N Y Acad Sci* 2005; 1060: 387–94.
6. Bangert M, Schlaug G. Specialization of the specialized in features of external human brain morphology. *Eur J Neurosci* 2006; 24: 1832–34.
7. Elmer S, Hänggi J, Jäncke L. Interhemispheric transcallosal connectivity between the left and right planum temporale predicts musicianship, performance in temporal speech processing, and functional specialization. *Brain Struct Funct* 2016; 221: 331–44.
8. Li J, Luo C, Peng Y, Xie Q, Gong J, Dong L, et al. Probabilistic diffusion tractography reveals improvement of structural network in musicians. *PLoS One* 2014; 9: e105508.
9. Hutchinson S, Lee LH, Gaab N, Schlaug G. Cerebellar volume of musicians. *Cereb Cortex* 2003; 13: 943–9.
10. Schlaug G, Jancke L, Huang Y, Staiger JF, Steinmetz H. Increased corpus callosum size in musicians. *Neuropsychologia* 1995; 33: 1047–55.
11. Sluming V, Barrick T, Howard M, Cezayirli E, Mayes A, Roberts N. Voxel-based morphometry reveals increased gray matter density in Broca's area in male symphony orchestra musicians. *Neuroimage* 2002; 17: 1613–22.
12. Dekeyser S, De Kock I, Nikoubashman O, Bossche SV, Eetvelde RV, De Groote J, et al. "Unforgettable" - a pictorial essay on anatomy and pathology of the hippocampus. *Insights Imaging* 2017; 8: 199–212.
13. George EM, Coch D. Music training and working memory: an ERP study. *Neuropsychologia* 2011; 49: 1083–94.
14. Manjon JV, Coupe P. volBrain: An online MRI brain volumetry system. *Front Neuroinform* 2016; 10: 30.
15. Djamanakova A, Tang X, Li X, Faria AV, Ceritoglu C, Oishi K, et al. Tools for multiple granularity analysis of brain MRI data for individualized image analysis. *Neuroimage* 2014; 101: 168–76.
16. Whitfield-Gabrieli S, Nieto-Castanon A. Conn: a functional connectivity toolbox for correlated and anticorrelated brain networks. *Brain Connect* 2012; 2: 125–41.
17. Müller V, Lindenberger U. Dynamic orchestration of brains and instruments during free guitar improvisation. *Front Integr Neurosci* 2019; 13: 50.
18. Levitin DJ, Tirovolas AK. Current advances in the cognitive neuroscience of music. *Ann N Y Acad Sci* 2009; 1156: 211–31.
19. Bermudez P, Lerch JP, Evans AC, Zatorre RJ. Neuroanatomical correlates of musicianship as revealed by cortical thickness and voxel-based morphometry. *Cereb Cortex* 2009; 19: 1583–96.
20. Bermudez P, Zatorre RJ. Differences in gray matter between musicians and nonmusicians. *Ann N Y Acad Sci* 2005; 1060: 395–9.
21. Fauvel B, Groussard M, Chetelat G, Fouquet M, Landeau B, Eustache F, et al. Morphological brain plasticity induced by musical expertise is accompanied by modulation of functional connectivity at rest. *Neuroimage* 2014; 90: 179–88.
22. Groussard M, La Joie R, Rauchs G, Landeau B, Chetelat G, Viader F, et al. When music and long-term memory interact: effects of musical expertise on functional and structural plasticity in the hippocampus. *PLoS One* 2010; 5(10): e13225.
23. Marie D, Müller CA, Altenmüller E, De Villeet DV, Jünemann K, Scholz DS, et al. Music interventions in 132 healthy older adults enhance cerebellar grey matter and auditory working memory, despite general brain atrophy. *Neuroimage: Reports* 2023; 3: 100166.
24. Sato K, Kirino E, Tanaka S. A voxel-based morphometry study of the brain of university students majoring in music and nonmusic disciplines. *Behav Neurol* 2015; 2015: 274919.
25. Koutstaal W, Wagner AD, Rotte M, Maril A, Buckner RL, Schacter DL. Perceptual specificity in visual object priming: functional magnetic resonance imaging evidence for a laterality difference in fusiform cortex. *Neuropsychologia* 2001; 39: 184–99.
26. Amunts K, Schlaug G, Jancke L, Steinmetz H, Schleicher A, Dabringhaus A, et al. Motor cortex and hand motor skills: structural compliance in the human brain. *Hum Brain Mapp* 1997; 5: 206–15.

27. Kim YK, Shin SH. Comparison of effects of transcranial magnetic stimulation on primary motor cortex and supplementary motor area in motor skill learning (randomized, cross over study). *Frontiers in human neuroscience* 2014; 8: 937.
28. Lin KL, Kobayashi M, Pascual-Leone A. Effects of musical training on speech-induced modulation in corticospinal excitability. *Neuroreport* 2002; 13: 899–902.
29. Schlaug G. The brain of musicians: a model for functional and structural adaptation. *Annals of the New York Academy of Sciences* 2001; 930: 281–99.
30. Butler AJ, James T, Pavisian B, James KH. Neural differences in expert guitarists during over-learned non-standard visuomotor mapping of abstract versus concrete information. *Neurosci Lett* 2021; 17 (750): 135624.