



Subcutaneous Emphysema during Robotic-Assisted Radical Cystectomy

Robot-Yardımlı Radikal Sistektomi Sırasında Subkutan Amfizem

Ozkan GORGULU¹, Bora DİNÇ²

¹Antalya Training and Research Hospital, Department of Anesthesiology and Reanimation, Antalya, Turkey

²Akdeniz University School of Medicine, Department of Anesthesiology and Reanimation, Antalya, Turkey

Correspondence Address
Yazışma Adresi

Ozkan GORGULU
Antalya Training and Research
Hospital, Department of
Anesthesiology and Reanimation,
Antalya, Turkey
E-mail:
drozkanorgulu@hotmail.com

Received \ Geliş tarihi : 08.11.2018
Accepted \ Kabul tarihi : 31.12.2018
Online published : 15.04.2019
Elektronik yayın tarihi

Gorgulu O, Dinc B. Subcutaneous
emphysema during robot-assisted
radical cystectomy.
Akd Med J 2020;3:511-4.

Özkan GÖRGÜLÜ
ORCID ID: 0000-0002-1426-1725
Bora DİNÇ
ORCID ID: 0000-0001-5700-8917

ABSTRACT

Robotic-Assisted Radical Cystectomy (RARC) operations have become popular today due to early discharge and minimal blood loss. Besides, complications can develop with the prolongation of the operation time. In our case, we detected subcutaneous emphysema, which developed intraoperatively in RARC operation. Especially in RARC surgeries, it is essential to increase the respiratory frequency and provide optimal tidal volume with arterial blood gas evaluation because of the high intra-abdominal CO₂ pressures and Trendelenburg position for a long time. Also, we believe that careful physical examination of the patient is necessary in cases of increased End-tidal CO₂ levels intraoperatively.

Key Words: Subcutaneous emphysema, Robotic assisted cystectomy, High pressure insufflation

ÖZ

Robotik Yardımlı Radikal Sistektomi (RARC) ameliyatları erken taburculuk ve minimum kan kaybı nedeniyle günümüzde popüler hale gelmiştir. Ayrıca ameliyat süresinin uzaması ile komplikasyonlar gelişebilir. Olgumuzda da RARC ameliyatında intraoperatif gelişen deri altı amfizem tespit ettik. Özellikle RARC ameliyatlarında yüksek karın içi CO₂ basınçları ve uzun süre Trendelenburg pozisyonu nedeniyle arteriyel kan gazı değerlendirmesi ile solunum frekansının artırılması ve optimal tidal volümün sağlanması esastır. Ayrıca, intraoperatif tidal sonu CO₂ düzeylerinin artması durumunda hastanın dikkatli fizik muayenesinin gerekli olduğuna inanıyoruz.

Anahtar Sözcükler: Subkutan amfizem, Robotik yardımlı sistektomi, Yüksek basınçlı insüflasyon

INTRODUCTION

Although open radical cystectomy (ORC) is still frequently used for surgical treatment of muscle-invasive bladder cancer, laparoscopic radical cystectomy (LRC) and robotic-assisted laparoscopic radical cystectomy (RALC) are also widely performed (1,2). Studies have shown that LRC and RALC have several advantages such as decreased blood loss and more rapid recovery compared to ORC (3). Beside of these advantages, considerable complications can be detected with RALC such as subcutaneous emphysema (SE), pneumothorax, and pneumomediastinum secondary to carbon dioxide (CO₂) insufflation. Although it is rare, longer intraoperative times and prolonged insufflation into the peritoneum can increase the incidence of these complications (4). In the literature, there are some reports addressing of massive subcutaneous emphysema in robotic gynecological surgery. However, we did not encounter a report showing its occurrence during RALC (5,6). Thus, we report the

case of a 53-year-old male patient who underwent RALC with 15 mmHg intraabdominal CO₂ pressure and had subcutaneous emphysema perioperatively.

CASE

A 53-year-old male patient with American Society of Anesthesiologists Classification (ASA Class) 2 and T2N0M0 bladder papillary cancer disease was prepared for RALC operation. Following monitoring with electrocardiography (ECG), peripheral oxygen saturation (SpO₂) and intra-arterial blood pressure (IBP), general anesthesia was induced. Two percent lidocaine (1mg/kg) was implemented intravenously to reduce the pain due to propofol. After the induction of Propofol (3mg/kg) and fentanyl (1 µg/kg), rocuronium (0.6 mg/kg) was used for muscle relaxation. For maintenance of anesthesia 50% air-oxygen, remifentanyl (0.5 µg/kg/min) infusion and desflurane inhalation (1 MAC) was performed. Because bleeding was not expected during the operation, we did not set a central venous catheter and a 16-G peripheral venous catheter was used. After inserting a foley catheter into the bladder and an orogastric catheter, End-tidal CO₂ (EtCO₂) was monitored with capnography. When the bispectral index (BIS) was between 40-60 level maximum Trendelenburg position was obtained. After 20 minutes from the induction, 15 mmHg intraabdominal insufflation pressure was achieved for the operation. During the operation, according to the first arterial blood gas analysis, pH: 7,46 PaCO₂: 28.8 mmHg and PaO₂: 210 mmHg were measured. At the 2nd hour of the operation, although we increased the respiratory frequency, EtCO₂ value was still increased and that was the reason why we suspected emphysema and checked the patient with physical examination. We detected subcutaneous crepitations on both sides of the neck that indicated the emphysema and informed to surgical team. Intraabdominal CO₂ pressure decreased to 12 mmHg and the arterial blood values were then measured as pH: 7.27 and PaCO₂: 55.8 mmHg that was demonstrated with acidosis. After a while, EtCO₂ did not come to the normal range and insufflation pressure decreased to 10 mm Hg. At the 210th minute of the operation arterial blood gas analysis was; pH: 7.27 PaCO₂: 55.8 mmHg. In addition, the patient's general condition deteriorated due to the prolongation of the operation time with impaired oxygenation (O₂ saturation: 92). Despite the interventions, respiratory acidosis could not be corrected. Therefore, the surgical team was informed and the robotic surgery was terminated and changed to laparotomy for performing the ileal loop. The patient was transferred to the intensive care unit (ICU) after 6 hours of surgery and was extubated at 2 hours postoperatively. Arterial blood gas values after extubation were analysed as pH: 7.27 paCO₂: 38.4 mmHg and paO₂: 150 mmHg. Subcutaneous emphysema was detected in the x-ray image (Figure 1).

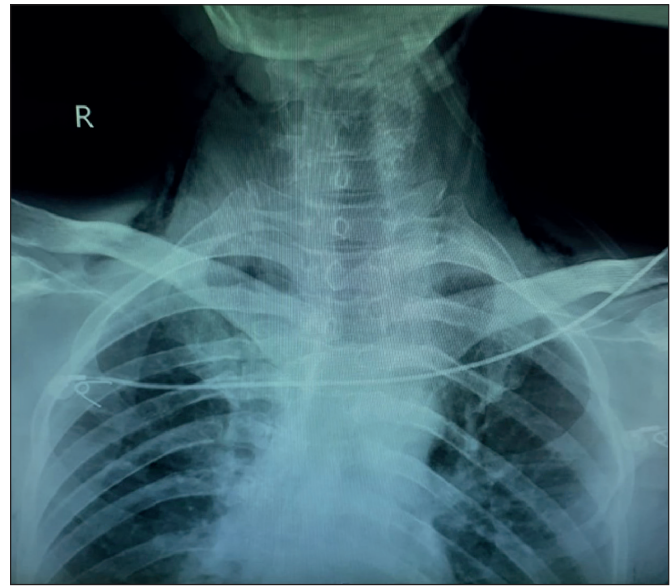


Figure 1: Postoperative radiograph (Subcutaneous emphysema on both side of the neck).

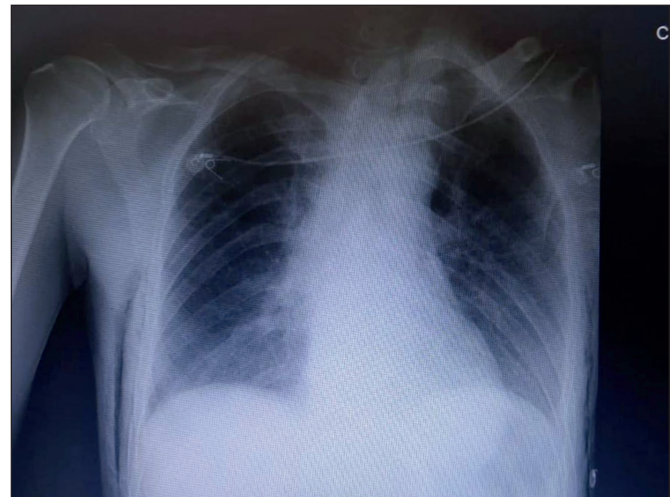

Figure 2: Subcutaneous emphysema.

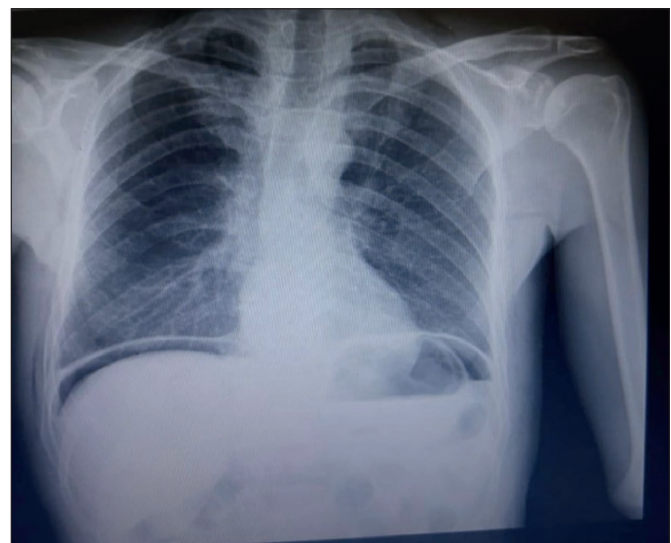


Figure 3: Postoperative day-2 radiograph (Subcutaneous emphysema resolved).

After the extubation, the patient was evaluated with a chest x-ray (Figure 2). At the postoperative day-1 subcutaneous crepitations were still present and pH: 7.39, PaCO₂: 41.1 mmHg PaO₂: 150 mmHg were measured. The radiological signs were clear in postoperative day-2 (Figure 3).

DISCUSSION

Open radical cystectomy is the first choice for the treatment of muscle-invasive bladder cancer (MIBC) because of the higher cure rate compared to other methods such as radiotherapy or chemotherapy (4). It provides approximately 50-59% ten-year recurrence-free survival rates and 45% overall survival rate (5). Although open radical cystectomy is described as a gold standard treatment method of MIBC, minimally invasive methods have gained in popularity in recent years. Because of similar oncological outcomes and less invasive approach and less blood loss and lower perioperative and postoperative complications, RLC and RALC have been the reason for surgical preference (6). In our case RALC was used for the surgical procedure. Besides many advantages, some complications have been described as subcutaneous emphysema, hypercarbia, pneumothorax or pneumomediastinum with RLC or RALC. Murdock et al. reported the rates of 5,5% hypercarbia, 2,3% subcutaneous emphysema, and 1,9% pneumothorax/pneumomediastinum following laparoscopic surgery (7). It has also been reported in several studies that the risk of subcutaneous emphysema, pneumothorax or pneumomediastinum had increased when the EtCO₂>50 mmHg and operative time was >200 min (8). In our case EtCO₂ was >50 mmHg at the 120. min. of operation and also the operation time was longer than 200 min. When the abdominal CO₂ pressure is 15 mmHg, the diaphragm movement decreases. With the decrease of functional residual capacity, the pulmonary CO₂ excretion decreases. Additionally, the absorption of CO₂ from subcutaneous tissues may lead increase of intraarterial CO₂ levels. When we noticed the hypercarbia we increased the

respiratory frequency and also reduced the intraabdominal CO₂ pressure to 12 mmHg. But EtCO₂ did not fall below 50 mmHg, so we suspected from subcutaneous emphysema and controlled the patient with the physical examination. Application of more than 30 degrees of Trendelenburg position in RARC leads to a decrease in lung functional residual capacity. This disrupts oxygen-carbon dioxide gas exchange and increases carbon dioxide retention. The EtCO₂ should be monitored closely in these patients. Any elevation here should be managed by placing the patient in the reverse Trendelenburg position and laparoscopy should be terminated (9). In order to prevent the deepening of respiratory acidosis and to decrease the morbidity and mortality with the prolongation of operation, laparotomy was recommended. When we informed the surgical team about hypercarbia and crepitations, CO₂ insufflation was finished and they changed the operation to laparotomy. Subcutaneous emphysema was resolved spontaneously through observation in the intensive care unit on postoperative day-2 (Figure 3).

This situation points out that we must be careful about subcutaneous emphysema during the laparoscopic surgeries if intraabdominal CO₂ pressure >12 mmHg. As it is similar to other studies, it may alert us about a subcutaneous emphysema when EtCO₂>50 mmHg though increasing respiratory frequency. In this situation, we should check out the patient with a careful physical examination. If there are any crepitation signs, it should be informed with the surgical team and insufflation may be finished and operation should be changed to laparotomy to avoid more critical complications such as pneumothorax or pneumomediastinum and cardiovascular disorders. Complications of high pressure of carbon dioxide insufflation should be kept in mind and the surgical team should be alerted about if the insufflation pressure is high for a long time. Thus, following cautions will effect mortality and morbidity rates in such cases.

REFERENCES

1. Fonseka T, Ahmed K, Froghi S, Khan SA, Dasgupta P, Shamim Khan M. Comparing robotic, laparoscopic and open cystectomy: A systematic review and meta-analysis. *Arch Ital Urol Androl* 2015; 87:41-8.
2. Li K, Lin T, Fan X, Xu K, Bi L, Duan Y, Zhou Y, Yu M, Li J, Huang J. Systematic review and meta-analysis of comparative studies reporting early outcomes after robot-assisted radical cystectomy versus open radical cystectomy. *Cancer Treat Rev* 2013; 39:551-60.
3. Bochner BH, Dalbagni G, Sjoberg DD, Silberstein J, Keren Paz GE, Donat SM, Coleman JA, Mathew S, Vickers A, Schnorr GC, Feuerstein MA, Rapkin B, Parra RO, Herr HW, Laudone VP. Comparing open radical cystectomy and robot-assisted laparoscopic radical cystectomy: A randomized clinical trial *Eur Urol* 2015; 67:1042-50.
4. Ott DE. Subcutaneous emphysema-beyond the pneumoperitoneum *JSL* 2014; 18:1-7.

5. Celik H, Cremins A, Jones KA, Harmanli O. Massive subcutaneous emphysema in robotic sacrocolpopexy JSLS 2013; 17:245-8.
6. Patti L, Haussner W, Wei G. Diffuse subcutaneous emphysema, pneumomediastinum, and pneumothorax following robotic assisted laparoscopic hysterectomy. Case Reports Emerg Med 2017; 2017:2674216.
7. Murdock CM, Wolff AJ, Van Geem T. Risk factors for hypercarbia, subcutaneous emphysema, pneumothorax, and pneumomediastinum during laparoscopy. Obstet Gynecol 2000; 95:704-9.
8. Lehmann LJ, Lewis MC, Goldman H, Marshall JR. Cardiopulmonary complications during laparoscopy: Two case reports. South Med J 1995; 88:1072-5.
9. Srivastava A, Niranjana A. Secrets of safe laparoscopic surgery: Anaesthetic and surgical considerations. J Minim Access Surg 2010; 6(4):91-4.