



## Case Report

### Ligamentum Flavum Hematoma As a Rare Cause of Failed Back Surgery

Hakan AK<sup>1</sup>, Sevinç ŞAHİN<sup>2</sup>, İsmail GÜLŞEN<sup>3</sup>, Yurdanur AKYÜZ<sup>4</sup>, Selda SEÇKİN<sup>2</sup>

<sup>1</sup>Bozok Üniversitesi, Nöroşirurji Anabilim Dalı, Yozgat, Türkiye <sup>2</sup>Bozok Üniversitesi, Patoloji Anabilim Dalı, Yozgat, Türkiye <sup>3</sup>Yüzüncü Yıl Üniversitesi, Nöroşirurji Anabilim Dalı, Van, Türkiye <sup>4</sup>Bozok Üniversitesi, Radyoloji Anabilim Dalı, Yozgat, Türkiye

## Summary

Ligamentum flavum hematoma is a rare cause of root or spinal cord compression. It has been defined in the cervical, thoracic, and lumbar segments of the spine. Patients may present with the following symptoms radicular pain, hypoesthesia, loss of muscle power, and cauda equina syndrome due to the anatomic level of the lesion. Magnetic resonance imaging may provide helpful clues in the differential diagnosis of the disease. However, its diagnosis is established with intraoperative and pathological findings. Surgical decompression is the only therapeutic approach reported in the literature. Herein, we present a new case of ligamentum flavum hematoma as a possible cause of failed back in a 75-year old a man who had been operated three times before. After the last surgery, the complaints of the patient were resolved and the histopathological diagnosis was consistent with ligamentum flavum hematoma.

**Key words:** Ligamentum flavum hematoma, magnetic resonance imaging, surgical decompression, lumbar spine

### Başarısız Bel Cerrahisinin Nadir Bir Nedeni Olarak Ligamentum Flavum Hematomu

## Özet

Ligamentum flavum hematomu spinal kök veya spinal kord kompresyonunun nadir bir nedenidir. Servikal, torakal ve lomber spinal segmentlerde tanımlanmıştır. Hastalar lezyonun anatomik seviyesine göre radiküler ağrı, duyu kusuru, kas gücü kaybı ve kauda ekuina belirtileri ile başvurabilirler. Manyetik rezonans görüntüleme bu hastalığın tansında önemli ip uçları sağlayabilmektedir. Bununla birlikte tanı operasyon esnasındaki bulgulara ve patolojik inceleme sonuçlarına dayanarak konulmaktadır. Cerrahi dekompresyon literatürde bildiren tek tedavi yaklaşımıdır. Bu yazıda 3 kez bel fıtığı nedeniyle ameliyat edilen ancak şikâyetleri düzelme göstermeyen, başarısız bel cerrahisi hastası olarak kabul edilen 75 yaşında bir olguda tespit edilen ligamentum flavum hematomu sunulmaktadır. Hastanın kiniğimizde yapılan son operasyonunda sonra şikâyetlerinde belirgin düzelme tespit edildi ve ligamentum flavum hematomu tanısı histopatolojik olarak desteklendi.

**Anahtar Kelimeler:** Ligamentum flavum hematomu, manyetik rezonans görüntüleme, cerrahi dekompresyon, lomber omurga

## INTRODUCTION

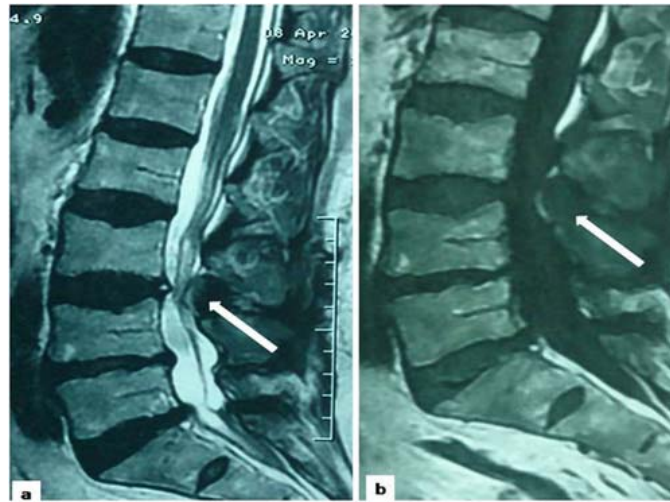Ligamentum flavum hematoma (LFH) is a rare cause of root and spinal cord compression. It has been defined in the cervical, thoracic, and lumbar segments of the spine<sup>(7,11,14)</sup>. Different signs and symptoms may be seen according to the level of compression<sup>(14)</sup>. Also, different etiological factors were reported as minor back injury, stepping onto a box, heavy lifting, sport exercises, and local injection<sup>(7,13)</sup>. However, in some cases no etiological factor was determined<sup>(13)</sup>. Magnetic resonance imaging may give important clues about preoperative diagnosis<sup>(8)</sup>. The main treatment approach is the surgery. Laminectomy, microsurgical decompression, or endoscopic approaches are the main procedures<sup>(13)</sup>.

## CASE PRESENTATION

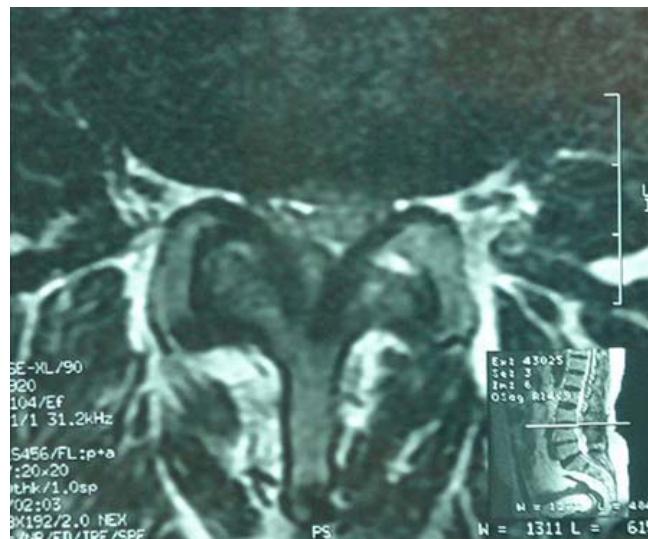A 75-year old man presented with pain in the back and both legs. His complaints were worsening during walking and forced him to sit down at about 50 meters. The pain was more severe on the right leg and numbness was also accompanying to pain. He had been operated three times before. They were performed two times for the right L5-S1 intervertebral discs and once for the right L4-5 intervertebral discs, because of the same complaints during last 8 months. But, he did not have any significant improvement in his complaints after these operations. His medical history was unremarkable except these 3 operations.

In neurological examination, there was hypoesthesia on the right L4-5, and S1 dermatomes. Straight leg raising test and

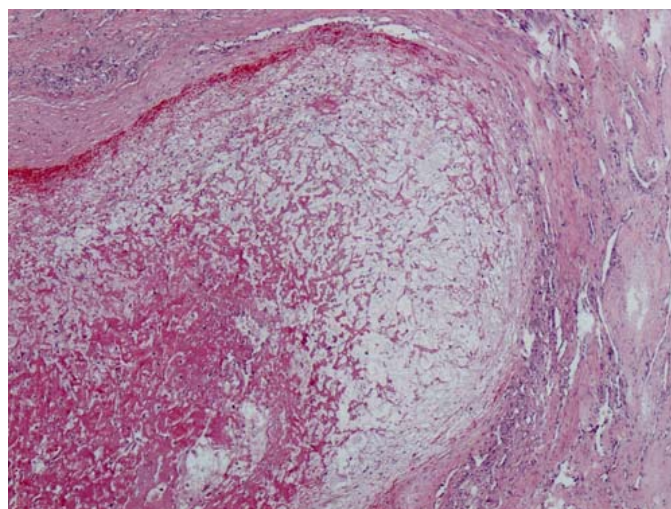
femoral nerve stretching test were positive on the right side. There was no loss of muscle strength. Deep tendon reflexes were decreased at patella and Achilles' tendons. Lumbosacral MRI revealed a lesion at L3-4 level which compressed the thecal sac, obvious in sagittal plane (Figure 1,2). It also revealed L5-S1 disc herniation that suggested recurrence or incomplete decompression. Additionally there was foraminal stenosis at the right L4-5 level. At the operation, discectomy and broad foraminotomy were performed for L4-5 and L5-S1 with L4 hemilaminectomy. For the lesion appeared on the MRI, L3 hemilaminectomy was performed. During flavectomy, ligamentum flavum was detected to be hardened and slightly cylindrical in shape on the right side. After excision, bluish points were observed on the flava. Rapid resolution of the clinical symptoms was determined soon after the operation. Histopathologically a hypocellular cystic area localized in the central part of fibrocollagenous tissue including some inflammatory cells and granulation tissue was detected (Figure 3). The cystic area were consisting of red blood cells, some foamy macrophages, elastic fibers, fibrin and mucin showing positivity with Alcian Blue (pH: 2.5) (Figure 4). In order to rule out malignancy (chordoma, mucinous carcinoma, and etc.) immunostaining was performed. Pancytokeratin, EMA, S100 and SMA were negative. Vimentin and CD68 were positive in the foamy macrophages. The histopathological and immunohistochemical findings were consistent with degenerative change and ligamentum flavum hematoma.



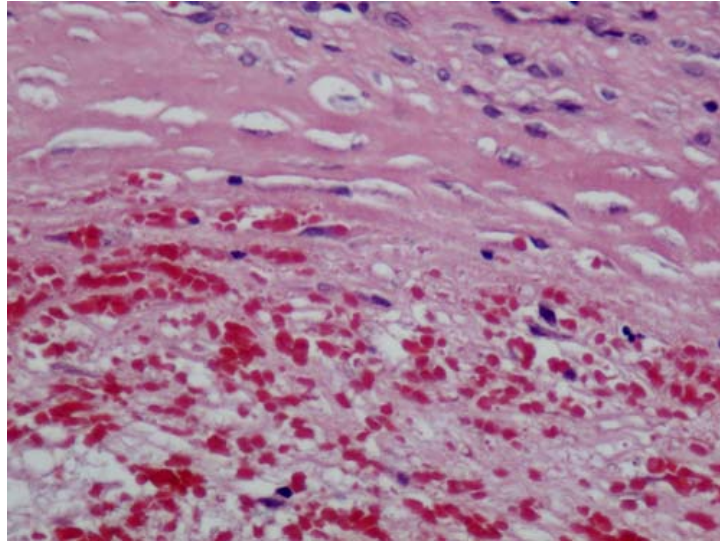
**Figure 1a&b:** T2 and T1 weighted MRI images on sagittal plane, white arrows indicating a circumscribed lesion.



**Figure 2:** T2 weighted MRI image on axial plane.



**Figure 3:** Photomicrograph showing well-defined hematoma in the ligamentum flavum (H&E, x40).



**Figure 4:** Red blood cells and degenerative elastic fibers in the hematoma (H&E, x400).

## DISCUSSION

Various neoplasms, infections, trauma, and spontaneous epidural hematoma may be encountered in the differential diagnosis of root or spinal cord compression, and herniated nucleus pulposus<sup>(1,6)</sup>. Additionally, a novel entity called ligamentum flavum hematoma has been reported in the differential diagnosis in the last 3 decades<sup>(2,3,4,6)</sup>.

Ligamentum flava are the longest ligamentous structure in the human body and consist of elastic fibers (80%) and collagen (20%)<sup>(7)</sup>. The main function of it is to help the maintenance of the erect posture (Hyun-woo lee). In fact, this ligament is poorly vascularized and only a few small vessels pass through it<sup>(7,9)</sup>. Thus, formation of a hematoma does not occur unless there is a major trauma, and degeneration or hypertrophy of it<sup>(9)</sup>.

LFH is extremely rare and only case reports were present in the literature<sup>(15)</sup>. The common features of the cases in the literature may be listed as following. Most of the patients were relatively older-aged, only a few of them were younger than 60 years old. It was more common in men than women about two folds. Most of the

cases in the literature were located in the lumbar segments, but some cases aroused in the cervical and thoracic segments. The onset of the symptoms was insidious and the complaints showed a progressive course in most of the cases. Additionally, all of the patients underwent surgery and the clinical outcomes were satisfactory<sup>(7,9)</sup>.

Most of the patients reported in the literature had a history of repeated minor back injury during daily activities or sports. However, there is only a case report that ligamentum flavum hematoma formation was observed after a spinal surgery. It was reported that the LFH aroused in the adjacent segment four years after a long level fusion<sup>(5)</sup>. In our case, there was no history of any trauma but there was a history of 3 discectomy operations. We could not obtain the previous radiological images, thus we could not exactly prove the presence of the hematoma prior to the previous operations. Although our radiological findings suggested that this was not an acute process, it could not give information about the exact time of hematoma formation.

The surgeons should be aware of both this novel entity and the lesions in the differential diagnosis of LFH including synovial cyst, ganglion cyst, discal cyst, and some tumors<sup>(6,17)</sup>. In the diagnosis of the LFH magnetic resonance imaging is the most helpful radiological technique<sup>(20)</sup>. However, signal intensity is equivocal because the intensity reflects the time course of the chemical change from oxyhemoglobin to hemosiderin in hematomas<sup>(16)</sup>. Generally, a well-circumscribed lesion that is slightly to moderately hyperintense to ligamentum flavum in the extradural space in T1-weighted images may be detected. Heterogenous intensity and areas of increased density within the hematoma may be determined<sup>(20)</sup>. Our radiological findings were a hypointense on T1 weighted and hyperintense well demarcated and round on T2 weighted MRI. The second most important diagnostic tool in the diagnosis is the pathological examination<sup>(16)</sup>.

Surgical intervention was applied to all of the cases reported in the literature. The aim in the surgical approach was to remove the expansive mass by laminectomy or partial laminectomy<sup>(5,10,12,14,18,19)</sup>. Recently, Takeno et al reported the microsurgical excision of the hematoma<sup>(17)</sup>. Additionally, in 2011 Ohba et al used the endoscopy in the surgical decompression<sup>(13)</sup>. Excellent clinical outcomes were obtained after the surgery using the whole reported methods of decompression. In our case, right sided hemilaminectomy for both of L4-5 and L5-S1 discectomy, and foraminotomy for excision of the lesion were performed. Also, posterior segmental instrumentation was done with pedicle screws because of intraoperatively defined instability. A satisfactory clinical outcome after surgery was also detected in our case as reported in the literature.

In conclusion, LFH is a rare and relatively novel entity that should be noted in the differential diagnosis of root or spinal cord

compression. The etiology, underlying mechanisms, and the preoperative diagnosis of the ligamentum flavum hematoma are still not clear. Thus, further studies and additional case reports will improve the data about it in the literature.

#### Correspondence to:

Hakan Ak

E-mail: [nrsdrhakanak@yahoo.com](mailto:nrsdrhakanak@yahoo.com)

**Received by:** 26 November 2013

**Revised by:** 06 December 2013

**Accepted:** 06 December 2013

#### The Online Journal of Neurological Sciences (Turkish) 1984-2013

This e-journal is run by Ege University  
Faculty of Medicine,

Dept. of Neurological Surgery, Bornova,  
Izmir-35100TR

as part of the Ege Neurological Surgery  
World Wide Web service.

Comments and feedback:

E-mail: [editor@jns.dergisi.org](mailto:editor@jns.dergisi.org)

URL: <http://www.jns.dergisi.org>

Journal of Neurological Sciences (Turkish)

Abbr: J. Neurol. Sci.[Turk]

ISSNe 1302-1664

#### REFERENCES

1. Ak H, Aydın V. Extrapulmonary small cell carcinoma of spine presenting with a thoracic epidural mass: case report. *Journal of Neurological Sciences [Turkish]*. 2012; 29(1): 136-40.
2. Cruz-Conde R, Berjano P, Buitron Z. Ligamentum flavum hematoma presenting as progressive root compression in the lumbar spine. *Spine* 1995; 20: 1506-9.
3. Hirakawa K, Hanakita J, Suwa H, Matsuoka N, Oda M, Muro H, Fukushima T. A post-traumatic ligamentum flavum progressive hematoma: a case report. *Spine* 2000; 25: 1182-4.

4. Holtas S, Heiling M, Lonnroft M. Spontaneous spinal epidural hematoma: findings at MR imaging and clinical correlation. *Radiology* 1996;199:409-13.
5. Kim HS, Kim SW, Lee SM, Shin H. Ligamentum flavum hematoma in the adjacent segment after a long level fusion. *J Korean Neurosurg Soc* 2011; 49 : 58-60
6. Kotil K, Bilge T. A ligamentum flavum hematoma presenting as an L5 radiculopathy. *Journal of Clinical Neuroscience* 2007; 14:994-7.
7. Lee H-W, Song J-H, Chang I-B, Choi H-C. Spontaneous ligamentum flavum hematoma in the rigid thoracic spine: a case report and review of the literature. *J Korean Neurosurg Soc.* 2008, 44:47-51.
8. Mahallati H, Wallace CJ, Hunter KM, Bilbao JM, Clark AW. MR Imaging of a Hemorrhagic and Granulomatous Cyst of the Ligamentum Flavum with Pathologic Correlation. *AJNR* 1999; 20: 1166-8.
9. Minamide A, Yoshida M, Tamaki T, Natsumi K. Ligamentum flavum hematoma in the lumbar spine. *J Orthop Sci.* 1999;4:376-9.
10. Miyakoshi N, Shimada Y, Okada K, Hongo M, Kasukawa Y, Itoi E. Ligamentum flavum hematoma in the rigid thoracic spinal segments: case report. *J Neurosurg Spine.* 2005;2(4):495-7.
11. Miyakoshi N, Shimada Y, Kasukawa Y, Ando S. Ligamentum flavum hematoma in the cervical spine. *Neurol Med Chir (Tokyo)* 2006, 46:556-8.
12. Mizuno J, Nakagawa H, Inoue T, Hashizume Y. Ligamentum flavum hematoma in the lumbar spine. *Neurol Med Chir (Tokyo).* 2005;45(4):212-5.
13. Ohba T, Ebata S, Ando T, Ichikawa J, Clinton D, Haro H: Lumbar ligamentum flavum hematoma treated with endoscopy. *Orthopedics* 201; 34(7): e324-e327. DOI: 10.3928/01477447-20110526-27.
14. Sfreddo E, Guerra MTE. Ligamentum flavum hematoma: a case report and literature review. *Coluna/Columna.* 2012; 11(1): 81-3.
15. Sweasey TA, Coester HC, Rawal H, Blaivas M, McGillicuddy JE. Ligamentum flavum hematoma. Report of two cases. *J Neurosurg* 1992; 76: 534-7.
16. Takahashi M, Satomi K, Hasgawa A, Hasegawa M, Taki N, Ichimura S. Ligamentum flavum hematoma in the lumbar spine. *J Orthop Sci.* 2012; 17: 308-12.
17. Takeno K, Kobayashi S, Miyazaki T, Yayama T, Baba H. Microsurgical excision of hematoma of the lumbar ligamentum flavum. *Joint Bone Spine* 2010; 77: 351-4.
18. Tamura T, Sakai T, Sairyo K, Takao S, Kagawa S, Katoh S, et al. Hematoma in the cervical ligamentum flavum. Report of a case and review of the literature. *Skeletal Radiol.* 2010;39(3):289-93.
19. Yamaguchi S, Hida K, Akino M, Seki T, Yano S, Iwasaki Y. Ligamentum flavum hematoma in the lumbar spine. *Neurol Med Chir (Tokyo).* 2005;45(5):272-6.
20. Yüceer N, Baskaya MK, Smith P, Willis BK. Hematoma of the ligamentum flavum in the lumbar spine: case report. *Surg Neurol.* 2000; 53: 598-600.